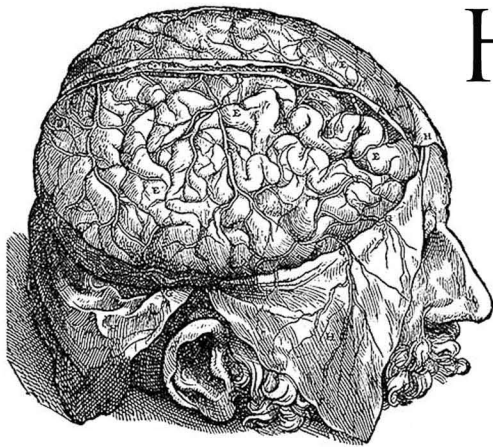


# ANATOMY OF THE HUMAN BODY

## PART 4



# HENRY GRAY



- 01 - NEUROLOGY: STRUCTURE OF THE NERVOUS SYSTEM, PART 1
- 02 - STRUCTURE OF THE NERVOUS SYSTEM, PART 2
- 03 - DEVELOPMENT OF THE NERVOUS SYSTEM, PART 1
- 04 - DEVELOPMENT OF THE NERVOUS SYSTEM, PART 2
- 05 - THE SPINAL CORD, PART 1
- 06 - THE SPINAL CORD, PART 2
- 07 - THE SPINAL CORD, PART 3
- 08 - THE BRAIN; THE HIND-BRAIN, PART 1
- 09 - THE HIND-BRAIN, PART 2
- 10 - THE HIND-BRAIN, PART 3
- 11 - THE HIND-BRAIN, PART 4
- 12 - THE MID-BRAIN
- 13 - THE FORE-BRAIN, PART 1
- 14 - THE FORE-BRAIN, PART 2
- 15 - THE FORE-BRAIN, PART 3
- 16 - THE FORE-BRAIN, PART 4
- 17 - THE FORE-BRAIN, PART 5
- 18 - COMPOSITION AND CENTRAL CONNECTIONS OF SPINAL NERVES
- 19 - COMPOSITION AND CONNECTIONS OF CRANIAL NERVES, PART 1
- 20 - COMPOSITION AND CONNECTIONS OF CRANIAL NERVES, PART 2
- 21 - COMPOSITION AND CONNECTIONS OF CRANIAL NERVES, PART 3
- 22 - COMPOSITION AND CONNECTIONS OF CRANIAL NERVES, PART 4
- 23 - PATHWAYS FROM THE BRAIN TO THE SPINAL CORD
- 24 - MENINGES OF THE BRAIN AND MEDULLA SPINALIS, PART 1
- 25 - MENINGES OF THE BRAIN AND MEDULLA SPINALIS, PART 2:  
CEREBROSPINAL FLUID 13 MB 9.31 MB 6.46 MB
- 26 - CRANIAL NERVES: OLFACTORY NERVES; OPTIC NERVE
- 27 - OCULOMOTOR NERVE; TROCHLEAR NERVE 5.
- 28 - TRIGEMINAL NERVE, PART 1
- 29 - TRIGEMINAL NERVE, PART 2
- 30 - ABDUCENT NERVE; FACIAL NERVE
- 31 - ACOUSTIC NERVE; GLOSSOPHARYNGEAL NERVE

- 32 - VAGUS NERVE
- 33 - ACCESSORY NERVE; HYPOGLOSSAL NERVE
- 34 - THE SPINAL NERVES
- 35 - POSTERIOR DIVISIONS
- 36 - ANTERIOR DIVISIONS, PART 1
- 37 - ANTERIOR DIVISIONS, PART 2
- 38 - ANTERIOR DIVISIONS, PART 3
- 39 - THE THORACIC NERVES
- 40 - THE LUMBOSACRAL PLEXUS
- 41 - SACRAL AND COCCYGEAL NERVES, PART 1
- 42 - SACRAL AND COCCYGEAL NERVES, PART 2
- 43 - THE SYMPATHETIC NERVES
- 44 - CEPHALIC AND CERVICAL PORTIONS OF SYMPATHETIC SYSTEM
- 45 - THORACIC, ABDOMINAL, AND PELVIC PORTIONS OF SYMPATHETIC SYSTEM
- 46 - GREAT PLEXUSES OF THE SYMPATHETIC SYSTEM
- 47 - THE ORGANS OF THE SENSES; THE ORGANS OF TASTE
- 48 - THE ORGAN OF SMELL
- 49 - THE ORGAN OF SIGHT
- 50 - TUNICS OF THE EYE, PART 1
- 51 - TUNICS OF THE EYE, PART 2
- 52 - THE REFRACTING MEDIA
- 53 - ACCESSORY ORGANS OF THE EYE, PART 1
- 54 - ACCESSORY ORGANS OF THE EYE, PART 2
- 55 - THE ORGAN OF HEARING
- 56 - THE EXTERNAL EAR
- 57 - THE MIDDLE EAR OR TYMPANIC CAVITY
- 58 - THE AUDITORY OSSICLES
- 59 - THE INTERNAL EAR OR LABYRINTH, PART 1
- 60 - THE INTERNAL EAR OR LABYRINTH, PART 2
- 61 - PERIPHERAL TERMINATIONS OF NERVES OF GENERAL SENSATIONS
- 62 - THE COMMON INTEGUMENT, PART 1
- 63 - THE COMMON INTEGUMENT, PART 2

Read by: ML Cohen, Veronica Jenkins, Laurie Anne Walden, Lee Ann Howlett, MorganScorpion, J.M. Smallheer, Bellona Times, David Lawrence, Annise, Anna Simon